

REVIEW

Open Access



# Ameloblastomas: current aspects of the new WHO classification in an analysis of 136 cases

Ana Maria Hoyos Cadavid<sup>1\*</sup> , Juliane Piragine Araujo<sup>1</sup>, Cláudia Malheiros Coutinho-Camillo<sup>2</sup>, Sheyla Bologna<sup>1</sup>, Celso Augusto Lemos Junior<sup>1</sup> and Silvia Vanessa Lourenço<sup>1</sup>

## Abstract

**Introduction:** Ameloblastomas are neoplasms that have inspired great controversy and clinical interest; their incidence, radiographic features, treatment and behavior are still discussed quite often in the literature. In 2017, the classification of these lesions underwent modifications in terminology with the introduction of prospective views based on updates in current genetic studies.

**Objective:** To describe the most important features of the new classification, as well as to evaluate the prevalence and the clinical and radiographic characteristics of 136 ameloblastomas.

**Methodology:** The clinical-pathological characteristics of 136 patients diagnosed with ameloblastoma in two large hospitals in São Paulo were analyzed. All the hematoxylin-eosin (HE) stained slides were reviewed using an optical microscope (Olympus Cover) and tumors were classified according to the new WHO criteria (2017). Two independent evaluators analyzed the slides; in cases where there was disagreement a third evaluator was used and the result was established in consensus.

**Results:** 71% of the lesions were of the conventional type, the predominant histopathological pattern being plexiform (40%), 72% of the tumors showed cortical expansion, and 84% had a radiographic pattern of the multilocular type. The treatment of choice in most cases was segmental resection (45%) and recurrence was present in 13% of the cases.

**Conclusion:** Studies with clinical-pathological correlations will be necessary in the near future, in order to provide new therapies that are more effective and conservative, improving the quality of life of patients affected.

**Keywords:** Ameloblastoma, Neoplasms, Odontogenic tumors, Oral pathology

## Background

Since the first edition of the World Health Organization (WHO) classification in 1971, odontogenic tumors (OT) have been intensively studied. These lesions attract the interest of pathologists and maxillofacial surgeons due to their low frequency, representing only 2–3% of all lesions of the jaws. (Philipsen and Reichart 2006) Ameloblastomas are benign odontogenic tumors of epithelial origin, uncommon, locally aggressive and being able to reach large sizes. (Milman et al. 2016; Sham et al. 2009) If left untreated, they are able to reach large sizes,

causing facial disfiguration and functional problems. There is no predilection for sex and its highest incidence is in the third and fourth decades of life. (Sham et al. 2009; Bassey et al. 2014)

In 2014 important studies on the genetics of ameloblastomas were published. Crucial to its etiopathogenesis and understanding, these studies identified highly recurrent mutations in mitogen-activated protein kinase (MAPK) and Hedgehog (SHH) signaling pathways. (Wright and Vered 2017)

The objective of this manuscript is to describe the most important features of the new ameloblastoma classification, as well as to evaluate the prevalence and the clinical and radiographic characteristics of 136 lesions.

\* Correspondence: [ana\\_hoyosc@hotmail.com](mailto:ana_hoyosc@hotmail.com)

<sup>1</sup>Department of Stomatology, School of Dentistry, University of São Paulo, Avenida Professor Lineu Prestes, Butantã São Paulo, SP 2227, Brazil  
Full list of author information is available at the end of the article



### New classification of Ameloblastomas (OMS)

The new version simplified classification into 3 types: conventional, unicystic and peripheral. The solid/multicystic term was discarded, as it could be confused with the unicystic type. Desmoplastic ameloblastoma was also reclassified as a histological subtype and not as a clinical-pathological entity, based on the fact that it behaves like any conventional ameloblastoma, although its clinical and radiographic characteristics are peculiar (Speight and Takata 2018; Dias et al. 2013) (Fig. 1).

Out of these types, conventional ameloblastoma is the most common, representing 85% of all ameloblastomas, and occurs mainly in the 3rd and 4th decades of life. (Sham et al. 2009; Hertog et al. 2012) Its biological behavior is considered more aggressive due to its higher incidence of recurrence. (Sham et al. 2009) Histologically it can be divided into follicular, plexiform, acanthomatous and granular cell morphological patterns; other less common histological variants are clear cell and desmoplastic cells. In general, one-third of the conventional type has a plexiform pattern, one-third a follicular pattern, and the remaining third corresponds to the other variants. It is currently accepted that there is no relationship between histological pattern and tumor behavior or prognosis. In addition, it is not uncommon for the same ameloblastoma to present different histological patterns (Dias et al. 2013; Hertog et al. 2012; Reichart et al. 1995) (Fig. 2).

Unicystic ameloblastomas (AU) are neoplastic entities characterized by a cystic morphological appearance covered by an ameloblastic epithelium that may present tumor growth to the lumen and the fibrous connective tissue. (Filizzola et al. 2014) Based on its histopathological characteristics, it presents 3 histological subtypes, characterized by the proliferation pattern of the epithelial component into: luminal, intraluminal and mural. Luminal and intraluminal variants respond satisfactorily

to conservative surgical approaches, whereas the mural variant presents higher rates of recurrence, and is thus treated in the same manner as conventional ameloblastomas. (Wright and Vered 2017) (Fig. 3).

Peripheral ameloblastoma is the least common variant, accounting for only 1% of cases. It primarily affects patients with a mean age of 52 years and occurs most frequently in the gingiva of the mandible. It rarely presents recurrences, even when treated conservatively. (Sham et al. 2009) The histopathological aspect is represented by islands of ameloblastic epithelium with a pattern similar to the conventional type. (Sham et al. 2009; Effiom et al. 2018)

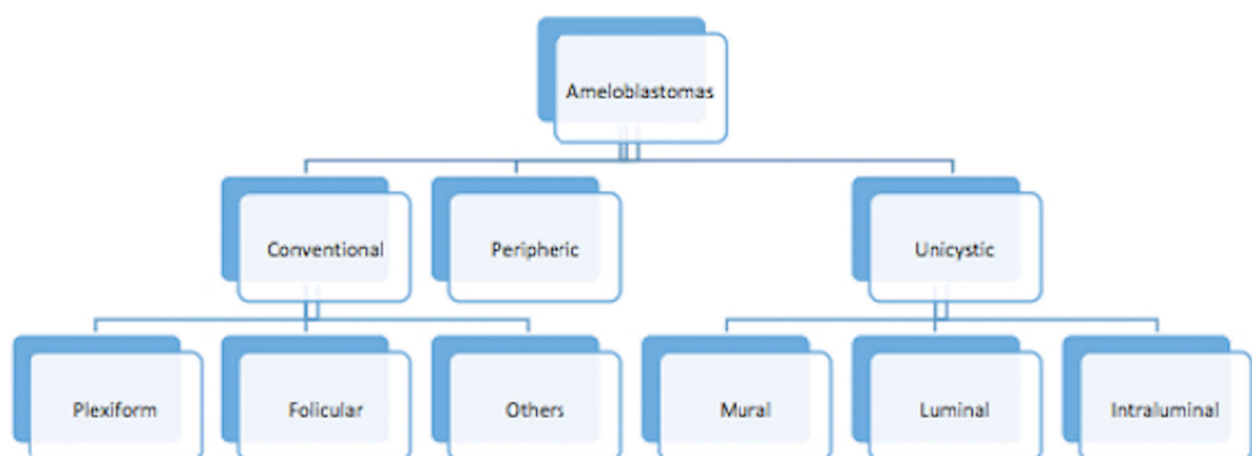
### Materials and methods

In this critical, in light of the new WHO classification published in 2017, review of the literature we analyzed the clinical-pathological characteristics of 136 patients diagnosed with ameloblastoma in 2 large hospitals in São Paulo (Hospital das Clínicas - Medical School of the University of São Paulo and AC Camargo Cancer Center, São Paulo). The clinical and radiographic information was retrieved from the hospital database (with the approval of the research ethics committee, under protocol number 171/08 approval FR-216880).

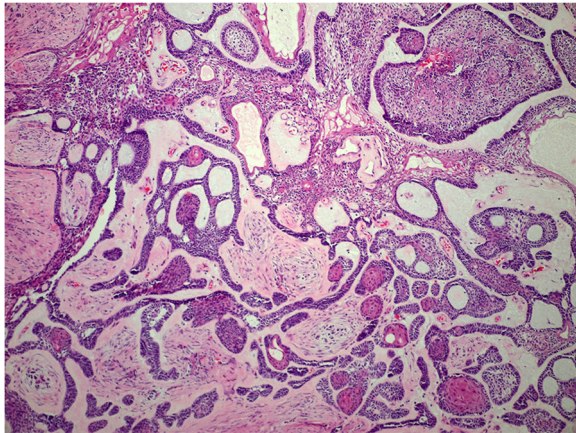
All slides stained with hematoxylin-eosin (HE) were reviewed using an optical microscope (Olympus Cover) and tumors were classified according to WHO criteria (2017). Two independent evaluators analyzed the slides, and in cases where there was disagreement a third evaluator was called upon and the result was established in consensus.

### Results

This study included 136 patients, most of which were Caucasian (63.9%); the mean age was 33.6 years, ranging



**Fig. 1** Flowchart with the new classification of ameloblastomas - WHO2017

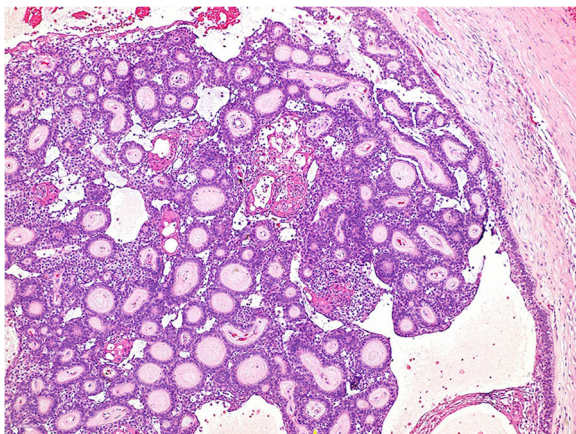


**Fig. 2** Conventional ameloblastoma presenting multiple patterns: plexiform, follicular and acanthomatous (Original Magnification  $\times 100$ )

from 9 to 82 years. The majority of patients were male, with 71 men (52%) and 65 women (48%).

The main complaints were swelling in the involved area (85%) and/ or pain (29%). Most cases were located in the posterior region of the mandible (83.1%) and had been treated with segmental resection (45%), curettage with cryotherapy (40%) and curettage alone (15%). Table 1 gives further detail as to the distribution of all cases.

Based on the new WHO classification (2017), (Wright and Vered 2017) our sample was divided into: 97 conventional (71.3%), 37 unicystic (27.2%) and two cases of peripheral ameloblastomas (1.5%); Among the histological subtypes, the plexiform pattern was the most representative (40%), followed by the follicular (36%), and the other subtypes: acanthomatous, granular, desmoplastic



**Fig. 3** Unicystic ameloblastoma showing intraluminal proliferation in follicular and acanthomatous pattern (Original Magnification  $\times 100$ )

**Table 1** Clinical and histopathological features of 136 lesions

Variable	Category	Total	(%)
Age	0–29 y.o	64	47
	30–59 y.o	57	42
	60–89 y.o	15	11
Ethnicity	Leucoderma	87	63.9
	Melanoderma	46	33.8
	Xantoderma	2	1.5
	Feoderma	1	0.7
Gender	Female	65	48
	Male	71	52
Location	Mandible posterior	113	83.1
	Mandible anterior	13	9.5
	Maxilla posterior	9	6.6
	Maxilla anterior	1	0.7
Treatment	Segmental resection	61	45
	Curettage + criotherapy	54	40
	Curettage	21	15
Histopathologic features	Plexiform	54	40
	Follicular	49	36
	Others	33	24

and basaloid cells which corresponded in total to 24% of all lesions. The histological classification of these lesions was based on the most predominant subtype, considering that the presence of more than one histological subtype was observed.

The conventional ameloblastomas in this study represented the highest percentage of these tumors (71.3%), most of them diagnosed in the fourth decade of life (58.7%), with a slight preference for men and located mainly in the posterior region of the mandible (91.8%). Most of them (84%) were radiographically multilocular, 72% showed expansion and 28% discontinuity of the vestibular or lingual bone plate.

The diagnosis of unicystic ameloblastoma was confirmed in 37 cases, occurring mainly in young patients (75.6%), with a mean age in the third decade of life and predilection for the posterior region of the mandible (92%). Most cases were classified in the mural subtype (94%).

The cases of extraosseous lesions were characterized by masses of tumor tissue, located in the buccal mucosa (100%), and involved 2 male patients 29 and 39 years old. Histologically the plexiform and follicular patterns were observed.

The mean follow-up time was 10 years and 18 patients presented recurrences (13.2%), 16 with conventional ameloblastoma and 2 with unicystic tumours.

## Discussion

Ameloblastomas may be associated with local morbidity but rarely with mortality. Its terminology, morphology, etiology, diagnosis and treatment remain controversial. (Philipsen and Reichart 2006; Wright and Vered 2017; Effiom et al. 2018; Siar et al. 2012) There are few studies evaluating the clinical-pathological characteristics of these lesions in Latin America, making this study of great importance due to the high rate of casuistry.

The etiologic factors described relate to the onset of the lesion after a local trauma, inflammation, nutritional deficiencies, mutations and/or molecular alterations, where different signaling pathways participate. More recent theories indicate the existence of genetic anomalies related to the appearance of ameloblastomas, enabling less aggressive treatments. (Brown and Betz 2015)

It is important to note that ameloblastomas represent approximately 11 to 18% of all OT, being the second most common after odontomas. It should be emphasized that there may be a difference in prevalence depending on where the study was performed; many hospital studies have a higher prevalence of ameloblastomas compared to those of universities. (Siar et al. 2012; Fregnani et al. 2002)

Considering gender, some studies have described that there is no predilection. (Intapa 2017; Ledesma-Montes et al. 2007) while others report predominance in men. (Reichart et al. 1995; Siar et al. 2012; Hong et al. 2007) In our study, 52% of the patients were male (Table 1).

Many authors report that there is no predilection for ethnicities. (Milman et al. 2016; Bassey et al. 2014; McClary et al. 2016) In this study 63.9% of the patients were leukoderma, 33.8% melanoderma, 1.5% xantodermas and 0.7% feodermas. Patients in the third and fourth decades of life are also reported to be more commonly affected. (Milman et al. 2016; Filizzola et al. 2014; Intapa 2017) as was also observed in our study, where age ranged from 9 to 82 years, similar to that found in the study by Milman et al. 2016. (Milman et al. 2016)

The signs and symptoms of swelling and pain in our patients were similar to those reported in previous studies. (-Milman et al. 2016; Sham et al. 2009; Intapa 2017; Saghravanian et al. 2016) Slow growth, progressive and expansive, are important behavioral characteristics of ameloblastomas, causing patients to often present asymptomatic facial asymmetries at more advanced stages of the lesion. (Siar et al. 2012)

The lesions could be intra or extra osseous, the mandible being mainly affected (80–85%), (Sham et al. 2009; McClary et al. 2016) with the mandible: maxilla ratio varying from 5:1 to 90:1. (Filizzola et al. 2014; Saghravanian et al. 2016) In our study, 83.1% of the tumors were

in the posterior region and 13 cases (9.5%) in the anterior region of the mandible; 9 cases were observed in the maxilla, 6.6% in the posterior region and one in the anterior region (0.7%).

The distribution of histological subtypes in our study is similar to that reported in the literature, and agrees with several studies where plexiform and follicular patterns are the most predominant. (Hertog et al. 2012; Filizzola et al. 2014; Siar et al. 2012; Saghravanian et al. 2016) Most cases of unicystic ameloblastoma were classified into the mural subtype (94.5%), a finding similar to other studies, where age, location and subtype were the same. (Filizzola et al. 2014)

Different modalities of imaging exams can be used for the evaluation, elaboration of the diagnostic hypothesis and planning for the treatment of these tumors. These include periapical, occlusal, panoramic, helical computed tomography (CT), cone beam computed tomography (CBCT) and magnetic resonance imaging (MRI). (Fujita et al. 2013) CT and CBCT are more commonly used to evaluate the bone characteristics of the tumor, whereas MRI provides details about the soft tissues involved by the lesion. (Milman et al. 2016; Sham et al. 2009; McClary et al. 2016)

Radiographically, ameloblastomas are observed as unilateral or multilocular radiolucent lesions with well-defined borders, which can cause root resorption and displacement of the teeth involved by the lesion. (Milman et al. 2016) Although suggestive, the final diagnosis should be confirmed by histopathological examination. The evaluation of the lesions was performed using CT, with 84% of the conventional tumors presenting multilocular features, 72% presenting buccal or lingual cortical expansion and 28% disruption of the buccal or lingual cortical. The base of the mandible presented bulging and rupture in 46 and 11% of the cases, respectively.

The treatment of ameloblastoma remains controversial because it is a benign, locally aggressive tumor with a high recurrence rate. In surgical planning, it is important to consider whether it is a primary or recurrent tumor; the age, size, location and duration of the lesion; the presence of cortical bone rupture; and soft tissue involvement. According to these variables, the treatment may be conservative or radical. (Fujita et al. 2013; Arotiba et al. 2005) Conservative treatment includes enucleation, enucleation associated with curettage, and the use of adjuvant therapies such as Carnoy's solution and cryotherapy. Radical treatment consists of marginal or block resection (1–2 cm margin) and immediate bone reconstruction. (Sham et al. 2009; Fujita et al. 2013; Sauk et al. 2010) Facial reconstruction procedures with iliac crest grafts or microvascular fibular flaps may be required. (-Milman et al. 2016; McClary et al. 2016)

In this study, the treatment of choice for most conventional ameloblastoma cases was segmental resection (45%), followed by curettage with cryotherapy (40%), and the remaining (15%) were treated with curettage only. The cases of unicystic ameloblastoma (luminal and intraluminal) and peripheral ameloblastoma were treated conservatively, i.e., with enucleation associated with curettage or cryotherapy; the other types (conventional and mural variant) required more invasive treatments. The efficacy of radiotherapy and chemotherapy were not established through controlled studies.(Sham et al. 2009; McClary et al. 2016)

Currently, there are targeted therapies due to recent advances in the understanding of the molecular signaling pathways associated with ameloblastoma pathogenesis.(Brown and Betz 2015; Sauk et al. 2010) MAPK-specific drugs (Mitogen-Activated Protein Kinases) selectively inhibit the functions of BRAF (B-Raf proto-oncogene) and MEK mutants to stop the deregulated proliferation and differentiation of ameloblastic cells. These therapies include vemurafenib and dabrafenib, which inhibit the mutated BRAF gene; trametinib, a mutated MEK gene inhibitor; and ponatinib and regorafenib which inhibit mutated FGFR2 (fibroblast growth factor receptor 2) genes. Mechanisms of resistance, such as the compensatory activation of the MAPK pathway by the epidermal growth factor receptor, were associated with vemurafenib treatment for ameloblastoma.(Effiom et al. 2018; Heikinheimo et al. 2015; Kurppa et al. 2014)

Similarly, targeted therapies have been developed to control the effect of the SMO mutation associated with ameloblastoma pathogenesis. These include vismodegib and itraconazole, which unfortunately have been less successful in the control of ameloblastomas associated with SMO W535 L and L412F mutations due to resistance mechanisms which block the binding of drugs directed at SMO.(Mishra et al. 2015) Contrarily, arsenic trioxide and KAAD-cyclopamine are highly effective against these same mutations and may be useful in the treatment of these tumors associated with the SHH signaling pathway.(Milman et al. 2016; Sweeney et al. 2014) As the expression of SHH is high in ameloblastomas, several drugs already used to antagonize SHH signaling offer other non-surgical targeted therapeutic options for patients with this type of tumor.(Mishra et al. 2015) Among these, cyclopamine is the most widely used, but its main disadvantage is the inhibition of osteoblastic proliferation and differentiation which are important for bone healing.(Effiom et al. 2018; Stanton and Peng 2010)

The prognosis is usually favorable, although it may cause deformities.(Milman et al. 2016; McClary et al. 2016) Relatively high relapse rates for this type of tumor remain a major challenge. Conventional ameloblastomas

treated with enucleation or curettage, present higher rates of recurrence when compared to unicystic ameloblastomas treated in the same manner.(Milman et al. 2016; Sham et al. 2009; Ledesma-Montes et al. 2007) The treatment indicated for recurrent ameloblastoma is radical surgery, which provides disease-free survival for at least 10 years(Hertog et al. 2011) but requires clinical and radiographic monitoring during this period of time.(Effiom et al. 2018) In this study, 18 cases presented recurrence (13.2%), 16 of which were conventional tumors and 2 were unicystic tumors. Of these, 9 cases were treated with curettage and cryotherapy, 5 with curettage and 4 with segmental resection.

In a recent study, it was observed that patients treated with conservative surgery had significantly higher recurrence rates when compared to cases submitted to segmental resection.(Hong et al. 2007) Our study corroborates with the data cited, since cases treated with curettage and cryotherapy or curettage only showed higher recurrence rates (28 and 50%, respectively), when compared with cases of segmental resection (22%). Understanding the behavior of this tumor is essential to avoid local morbidity and increased rates of relapse.

## Conclusion

Studies with clinical-pathological correlations will be necessary in the near future in order to provide new therapies that are more effective and conservative, thus improving the quality of life of these patients.

## Acknowledgements

The authors received financial support from FAPESP Fundação de amparo à pesquisa do estado de São Paulo, Hospital AC Camargo Center, grant number 2017/26990-8 and declare no potential conflicts of interest with respect to the authorship and/ or publication of this article.

## Authors' contributions

All the authors have made a substantial contribution to the work reported in the manuscript. All authors read and approved the final manuscript.

## Funding

This manuscript was supported by FAPESP Fundação de amparo à pesquisa do estado de São Paulo, grant number 2017/26990-8.

## Availability of data and materials

The data supporting the results of the present study are not publicly available; they belong to the AC Camargo Center Hospital database, but were used under license for the current study. However, if necessary, they are available upon reasonable request and with prior permission.

## Ethics approval and consent to participate

The research ethics committee of the AC Camargo Center Hospital under protocol number 171/8 FR-216880 approved the present manuscript.

## Consent for publication

Not applicable.

## Competing interests

This manuscript has not been considered for publication elsewhere, and all authors have seen and approved the final version. The authors also declare no conflict of interest.

**Author details**

<sup>1</sup>Department of Stomatology, School of Dentistry, University of Sao Paulo, Avenida Professor Lineu Prestes, Butanta Sao Paulo, SP 2227, Brazil.

<sup>2</sup>Department of Pathology, AC Camargo Cancer Center, Sao Paulo, Brazil.

**Received: 18 March 2019 Accepted: 20 May 2019**

**Published online: 14 June 2019**

**References**

- Arotiba GT, Ladeinde AL, Arotiba JT et al (2005) Ameloblastoma in Nigerian children and adolescents: a review of 79 cases. *J Oral Maxillofac Surg* 63: 747–751
- Bassey GO, Osunde OD, Anyanechi CE (2014) Maxillofacial tumors and tumor-like lesions in a nigerian teaching hospital: an eleven year retrospective analysis. *Afr Health Sci* 14:56–63
- Brown NA, Betz BL (2015) Ameloblastoma: a review of recent molecular pathogenetic discoveries. *Biomark Cancer* 7:19–24
- Dias CD, Brandão TB, Soares FA et al (2013) Ameloblastomas: clinical-histopathological evaluation of 85 cases with emphasis on squamous metaplasia and keratinization aspects. *Acta Odontol Scand* 71:1651–1655
- Effiom O, Ogundana O, Akinshipo A et al (2018) Ameloblastoma: current etiopathological concepts and management. *Oral Dis* 24:307–316
- Filizzola AI, Bartholomeu-Dos-Santos TCR, Pires FR (2014) Ameloblastomas: Clinicopathological features from 70 cases diagnosed in a single Oral pathology service in an 8-year period. *Med Oral Patol Oral Cir Bucal* 19: e556–e561
- Fregnani ER, Fillipi RZ, Oliveira CRGCM et al (2002) Odontomas and ameloblastomas: variable prevalences around the world? *Oral Oncol* 38: 807–808
- Fujita M, Matsuzaki H, Yanagi Y et al (2013) Diagnostic value of MRI for odontogenic tumours. *Dentomaxillofac Radiol* 42:1–9
- Heikinheimo K, Kurppa KJ, Elenius K (2015) Novel targets for the treatment of ameloblastoma. *J Dent Res* 94:237–240
- Hertog D, Bloemena E, Aartman IHA et al (2012) Histopathology of ameloblastoma of the jaws; some critical observations based on a 40 years single institution experience. *Med Oral Patol Oral Cir Bucal* 17:e76–e82
- Hertog D, Schulten EAJM, Leemans CR et al (2011) Management of recurrent ameloblastoma of the jaws; a 40-year single institution experience. *Oral Oncol* 47:145–146
- Hong J, Yun PY, Chung IH et al (2007) Long-term follow up on recurrence of 305 ameloblastoma cases. *Int J Oral Maxillofac Surg* 36:283–288
- Intapa C (2017) Analysis of prevalence and clinical features of ameloblastoma and its histopathological subtypes in Southeast Myanmar and lower northern Thailand populations: a 13-year retrospective study. *J Clin Diagn Res* 11:102–106
- Kurppa KJ, Catón J, Morgan PR et al (2014) High frequency of BRAF V600E mutations in ameloblastoma. *J Pathol* 232:492–498
- Ledesma-Montes C, Mosqueda-Taylor A, Carlos-Bregni R et al (2007) Ameloblastomas: a regional Latin-American multicentric study. *Oral Dis* 13: 303–307
- McClary AC, West RB, McClary AC et al (2016) Ameloblastoma: a clinical review and trends in management. *Eur Arch Otorhinolaryngol* 273:1649–1661
- Milman T, Ying G-S, Pan W et al (2016) Ameloblastoma: 25 year experience at a single institution. *Head Neck Pathol* 10:513–520
- Mishra P, Panda A, Bandyopadhyay A et al (2015) Sonic hedgehog Signalling pathway and Ameloblastoma - a review. *J Clin Diagn Res* 9:ZE10–ZE13
- Philipsen HP, Reichart PA (2006) Classification of odontogenic tumours. a historical review. *J Oral Pathol Med* 35:525–529
- Reichart PA, Philipsen HP, Sonner S (1995) Ameloblastoma: biological profile of 3677 cases. *Eur J Cancer B Oral Oncol* 31B:86–99
- Saghravani N, Salehinejad J, Ghazi N et al (2016) A 40-year retrospective clinicopathological study of ameloblastoma in Iran. *Asian Pac J Cancer Prev* 17:619–623
- Sauk JJ, Nikitakis NG, Scheper MA (2010) Are we on the brink of nonsurgical treatment for ameloblastoma? *Oral Surg Oral Med Oral Pathol Oral Radiol Endod* 110:68–78
- Sham E, Leong J, Maher R et al (2009) Mandibular ameloblastoma: Clinical experience and literature review. *ANZ J Surg* 79:739–744
- Siar CH, Lau SH, Ng KH (2012) Ameloblastoma of the jaws: a retrospective analysis of 340 cases in a Malaysian population. *J Oral Maxillofac Surg* 70: 608–615
- Speight PM, Takata T (2018) New tumour entities in the 4th edition of the World Health Organization classification of head and neck tumours: odontogenic and maxillofacial bone tumours. *Virchows Arch* 472:331–339
- Stanton BZ, Peng LF (2010) Small-molecule modulators of the sonic hedgehog signaling pathway. *Mol Biosyst* 6:44–54
- Sweeney RT, McClary AC, Myers BR et al (2014) Identification of recurrent SMO and BRAF mutations in ameloblastomas. *Nat Genet* 46:722–725
- Wright JM, Vered M (2017) Update from the 4th edition of the World Health Organization classification of head and neck Tumours: odontogenic and maxillofacial bone tumors. *Head Neck Pathol* 11:68–77

**Publisher's Note**

Springer Nature remains neutral with regard to jurisdictional claims in published maps and institutional affiliations.

**Ready to submit your research? Choose BMC and benefit from:**

- fast, convenient online submission
- thorough peer review by experienced researchers in your field
- rapid publication on acceptance
- support for research data, including large and complex data types
- gold Open Access which fosters wider collaboration and increased citations
- maximum visibility for your research: over 100M website views per year

**At BMC, research is always in progress.**

Learn more [biomedcentral.com/submissions](https://biomedcentral.com/submissions)

